

A Sudden Hand Color Changes in a Young Man

Hasan M. Isa^{1,2*} and Kawthar Mohamed Abdulla¹

¹Department of Pediatrics, Salmaniya Medical Complex, Manama, Bahrain

²Department of Pediatrics, Arabian Gulf University, Manama, Bahrain

Received: 13 June 2024

Accepted: 21 August 2024

*Corresponding author: halfaraj@hotmail.com

DOI 10.5001/omj.2025.40

A 21-year-old gentleman, who is a heavy smoker, presented to his local health center with a history of pain, numbness, tingling, and swelling in his fingers and both hands along with cold sensitivity. His symptoms started suddenly after one hour of his daily outdoor walk. He had similar attacks previously, which occurred without a specific reason and lasted for a variable amount of time ranging between short and long durations. He has no history of trauma, joint pain, rash, shortness of breath, or visual problems. On examination, the patient was comfortable in room air. His vital signs were within the normal range. Digital color changes, including white, red, and blue discoloration are shown in Figure 1. The complete blood count, inflammatory markers, anti-nuclear antibody, and rheumatoid factor test were unremarkable.

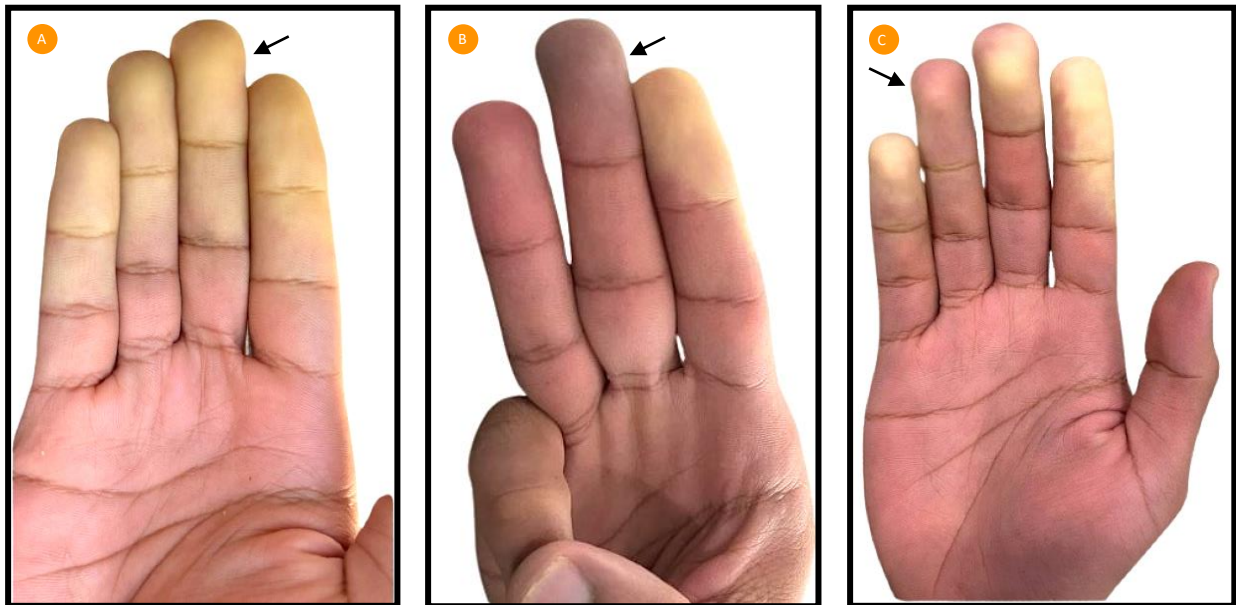


Figure 1: A picture of the hand of a young male diagnosed with primary Raynaud's phenomenon after exposure to cold, showing white (A), blue (B), and red (C) color changes (arrows).

Question

What is the diagnosis?

- a. Multiple sclerosis
- b. Scleroderma
- c. Raynaud's phenomenon
- d. Rheumatoid arthritis

Answer

- c. Raynaud's phenomenon

A primary Raynaud's phenomenon diagnosis was made. The patient was advised to avoid exposure to cold weather, stop smoking, do regular exercise as it improves circulation, and start nifedipine 30 mg daily for one month.

Discussion

Raynaud's phenomenon (RP) is an abnormal response to cold or emotional stress.¹ It has a characteristic clinical presentation of episodic vasoconstriction of the fingers associated with skin color changes, including white (blanching secondary to vasoconstriction) [Figure 1A], blue (cyanosis secondary to deoxygenation) [Figure 1B], and red (post-ischemic hyperemia) [Figure 1C].^{2,3} However, the presence of all three-color changes is not mandatory for diagnosing RP.⁴

Many factors can trigger RP, such as smoking, cold weather, sympathomimetic agents, and the use of vibratory tools.² Moreover, the severity of RP can be affected by subclinical atherosclerosis and a low body mass index, which can affect the physiological thermoregulatory response.²

Based on the underlying etiology, the disease can be classified as either primary or secondary RP.^{1,2} The primary RP is the commonest form, which is caused by functional vasospastic disorder.^{1,2} This form is reversible and benign. It may be associated with pain and numbness, which affect the hand's functions.^{1,2} The secondary RP has a wide range of pathological causes, including rheumatological, hematological, endocrinological, and vascular diseases.^{1,2} Specifically, conditions such as hand-arm vibration syndrome, carpal tunnel syndrome, hypothyroidism, connective tissue diseases such as systemic lupus erythematosus, systemic sclerosis, and vasculitis, and drug-related conditions such as the use of beta blockers, amphetamines, and cyclosporine, and so many other reported conditions can result in the secondary type of RP.^{1,2} Thus, it can result in a variety of clinical presentations and the effect of RP on each patient.² The secondary RP might progress to ulceration, scarring, or gangrene.¹

Laboratory testing for RP depends on the clinical presentation of each patient.² However, it should include the main investigations, such as a complete blood count, inflammatory markers, anti-nuclear antibody test, and thyroid function tests, to exclude any secondary cause.² The laboratory results of our patient excluded any secondary cause for his RP, suggesting the primary type of his disease.

Treatment of RP focuses on encouraging vasodilatation and/or suppressing vasoconstriction.¹ Supportive treatment is the main line of treatment in mild cases of RP, including avoiding cold exposure, smoking cessation, and lifestyle modifications.³ In addition, avoiding vasoconstriction stimulation substances, such as caffeine, ergot alkaloids, beta blockers, amphetamines, and cocaine is needed.³

Pharmacological treatment is required in cases where conservative treatment alone is not adequate.³ Commencing medical treatment for RP is based on its efficacy on each patient's condition and the severity of the symptoms.² In general, calcium channel blockers (CCBs) are the main pharmacological treatment for RP.³ However, long-term effects of CCBs are still unknown.⁵ It might reduce the frequency and severity of RP attacks, particularly in primary RP.⁵ Although critical side effects are rare, discontinuation of CCBs is required if side effects developed, such as hypotension, peripheral edema, and flushing.⁵ It is worth noting that our patient refused the use of nifedipine after knowing its possible side effects.

Disclaimers: The views expressed in the submitted report are our own and not an official position of any institution or funder.

Ethical approval: This report was conducted in accordance with the principles of Helsinki Declaration, and it was ethically waved by the Research and Research Ethics Committee, Salmaniya Medical Complex, Government hospitals, Kingdom of Bahrain

Conflict of interest: No financial or non-financial benefits have been received or will be received from any party related directly or indirectly to the subject of this article.

Contributor's statement: HMI and KMA were the main contributors in report design, drafting manuscript, and over-sight for all phases of the project and the final approval of the version to be published. All the authors have read and approved the final manuscript.

Data availability statement: Data will be made available on reasonable request.

References

1. Herrick AL. The pathogenesis, diagnosis and treatment of Raynaud phenomenon. *Nat Rev Rheumatol* 2012 Aug;8(8):469-479. <https://www.nature.com/articles/nrrheum.2012.96>.
2. Pauling JD, Hughes M, Pope JE. Raynaud's phenomenon-an update on diagnosis, classification and management. *Clin Rheumatol* 2019 Dec;38(12):3317-3330.
3. Block JA, Sequeira W. Raynaud's phenomenon. *Lancet* 2001 Jun;357(9273):2042-2048. <https://linkinghub.elsevier.com/retrieve/pii/S0140673600051187>.
4. Maverakis E, Patel F, Kronenberg DG, Chung L, Fiorentino D, Allanore Y, et al. International consensus criteria for the diagnosis of Raynaud's phenomenon. *J Autoimmun* 2014;48-49:60-65. <https://www.sciencedirect.com/science/article/pii/S0896841114000237>.
5. Rirash F, Tingey PC, Harding SE, Maxwell LJ, Tanjong Ghogomu E, Wells GA, et al. Calcium channel blockers for primary and secondary Raynaud's phenomenon. *Cochrane Database Syst Rev* 2017 Dec;12(12):CD000467. <https://www.cochranelibrary.com/cdsr/doi/10.1002/14651858.CD000467.pub2/full?cookiesEnabled>.