Multiple Ulcerated Nodules

Al Mu'tasim Al-Qassabi[1]*, Al Zahra Al Riyami[2] and Omaima Al Kamyani[3]

[1]Dermatology Department, Bahla Hospital, Bahla, Oman

[2]Medical officer dermatologist, Nizwa Polyclinic, Nizwa, Oman

[3]General foundation program, Oman Medical Specialty Board, Muscat, Oman

Received: 13 February 2023

Accepted: 28 March 2023

*Corresponding author: mhhh14@hotmail.com

DOI 10.5001/omj.2023.104

A previously healthy 42 years-old male from North Africa presented to the dermatology clinic with skin lesions over limbs and abdomen for 2 months. He reported minimal associated pruritus but no systemic complaints. Local skin examination showed three erythematous and ulcerated nodules over the left forearm, left flank, and right thigh [Figure 1]. The rest of the systemic examination was unremarkable. A bacterial swab from nodules was negative and treatment with oral antibiotics didn't help. A skin biopsy was obtained, and findings in high magnification are shown [Figure 2].

Figure 1: Ulcerated nodules.

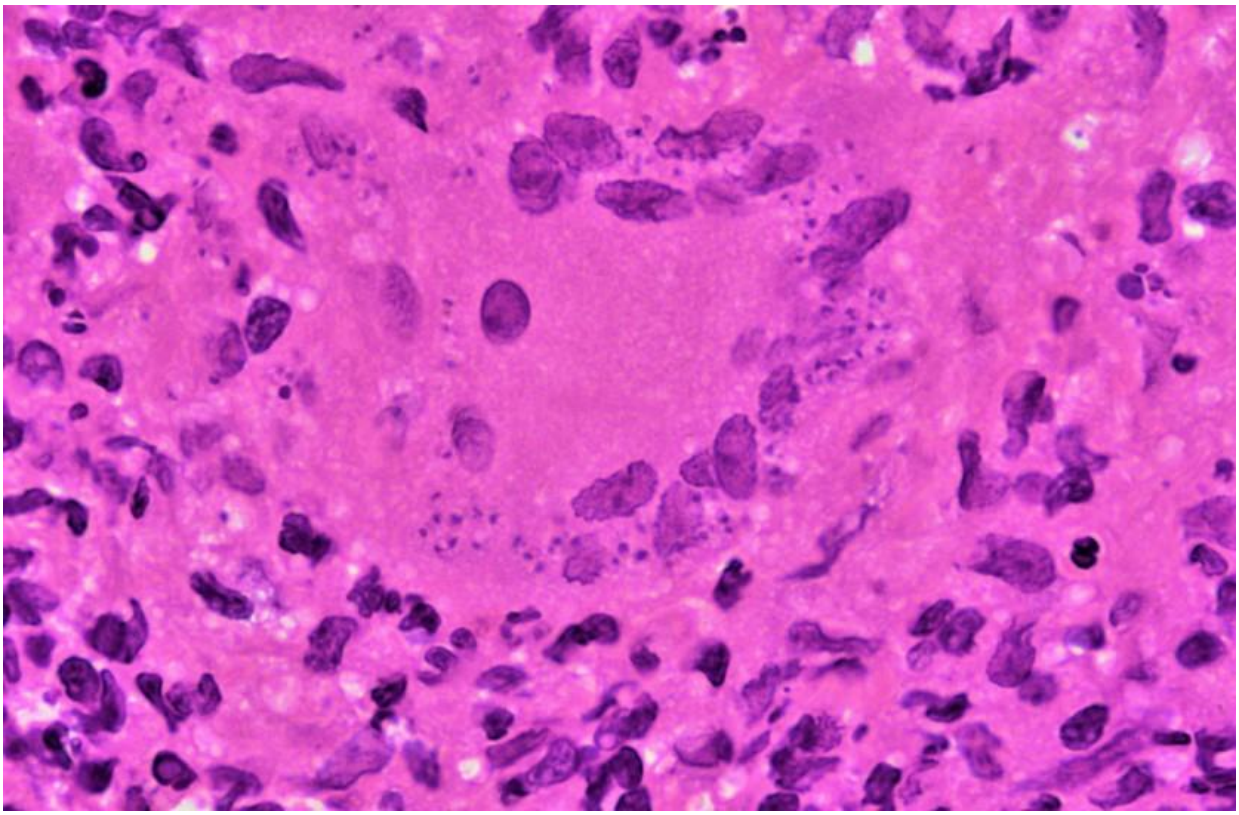

Figure 2: Skin biopsy.

Question

What is the most likely diagnosis?

a. Pyoderma Gangrenosum

b. Ecthyma

c. Cutaneous Leishmaniasis

d. Leprosy

Answer

C. Cutaneous Leishmaniasis

Skin biopsy demonstrated numerous amastigotes within histiocytes highlighted by Giemsa stain confirming clinical diagnosis of cutaneous leishmania. He was started on treatment with local cryotherapy sessions in combination with oral itraconazole 200 mg/day.

Discussion

Cutaneous leishmaniasis (CL), listed as an emerging and a neglected tropical disease by WHO, is a vector-borne infection caused by a heterogeneous group of protozoa belonging to the genus *Leishmania*; it is transmitted by sand fly vectors. At least twenty species of Leishmania are responsible for the different clinical forms of the disease in which CL is the most common form. CL is endemic in almost 100 countries Worldwide and affects 12 million cases. Localized CL typically present as solitary lesion, but multiple lesions do occur on exposed areas of the skin, especially the face and extremities. The initial lesion is a painless small red papule, which gradually enlarges up to 2 cm in diameter with typical Central ulceration. The incubation time between an infected sandfly bite and lesion development ranges from weeks to months.[1]

Diagnosis can be confirmed by demonstration of the parasite in a clinical specimen (usually skin) by histology, culture, or molecular analysis via polymerase chain reaction (PCR). There is no single universal treatment for CL. Some cases may resolve spontaneously but could leave a scar. Depending on the clinical severity of infection, treatments can be either local or systemic or combination. Local therapies include; pentavalent antimonials, paromomycin, cryotherapy, heat therapy and imiquimod while systemic therapies include; azoles antifungals, amphotericin, pentavalent antimonials and miltefosine. [2]

Acknowledgments

We would like to thank the patient for giving consent to publish the case and Dr. Zahra Al Abri, pathologist at Khoula hospital, for providing histopathology slides.

References

1. de Vries HJC, Schallig HD. Cutaneous Leishmaniasis: A 2022 Updated Narrative Review into Diagnosis and Management Developments. *Am J Clin Dermatol*. 2022;23(6):823-840.

2. Heras-Mosteiro J, Monge-Maillo B, Pinart M, et al. Interventions for Old World cutaneous leishmaniasis. *Cochrane Database Syst Rev*. 2017;11(11):CD005067.