

Acute Pericarditis as an Uncommon Presentation of Graves' Disease

Abdullah AL-Futaisi^{1*}, Moammar AL-Aamri², Fatima Fatima Bahowairath³ and Mahmood Saif Aljufaili⁴

¹Senior consultant endocrinologist at Sultan Qaboos University Hospital, Department of medicine, Oman

²Internal medicine residency program, Oman Medical Specialty Board, Oman.

³Department of medicine, Sultan Qaboos University Hospital, Oman.

⁴Emergency Medicine Department, Sultan Qaboos University Hospital

Received: 14 June 2020

Accepted: 12 July 2020

**Corresponding author: alfutaisia@gmail.com*

DOI 10.5001/omj.2020.82

Abstract

Cardiovascular manifestations are well recognized features of hyperthyroidism and particularly Graves' disease. Common cardiac complications include atrial fibrillation, hypertension and high or normal output congestive heart failure.(1) Few case reports have reported acute pericarditis as a rare manifestation of Graves' disease. There are several proposed mechanisms to explain the association between Graves' disease and acute pericarditis. We present a 28-year-old male who presented with acute pericarditis, and later confirmed to have Graves' disease.

Keywords: Acute Pericarditis; Graves' Disease; Autoimmune.

INTRODUCTION

Acute pericarditis is an inflammation of the pericardium, characterized by chest pain, pericardial friction rub and ECG changes. It is most commonly caused by viral infections. On the other hand, Graves' disease is an autoimmune disorder that causes hyperactivity of the thyroid gland. There has been a convincing evidence of a correlation between these two entities.⁽²⁾⁽³⁾⁽⁴⁾ Possible mechanisms include autoimmune link, a direct metabolic impact from acute thyrotoxicosis and antithyroid drugs induced pericarditis.

CASE REPORT

A 28-year-old gentleman presented to the emergency department with a four-day history of severe chest pain, localized to the left side, stabbing in nature and associated with palpitations, shortness of breath and sweating. He had no preceding symptoms of upper respiratory tract infection. He apparently had a similar episode a month ago when he was seen in a private hospital. He was told to have a fast heart rate on an ECG and given some IV medications. On further questioning, he gave history of weight loss of about 12 kg in past three months associated with tremors, sweating, anxiety and diarrhea. He had generalized weakness and was not able to attend his daily work. On examination in the emergency department, he was tachycardic with a heart rate of 110/min, his cardiovascular examination revealed a pericardial rub with normal dual heart sounds. He was thin built and he did not have a palpable goiter. His ECG showed widespread concave ST segment elevation without reciprocal changes and a PR segment elevation in lead aVR and PR depression in other leads, highly consistent with Stage-1 acute pericarditis [Figure 1].

He was admitted for evaluation. His laboratory investigations showed ESR 7 mm/hr and the troponin level was negative. His thyroid function showed an FT4 77.8 pmol/L (normal 7.9-14.4) and thyroid-stimulating hormone (TSH) 0.01 mIU/L (normal 0.34-5.6). There was no evidence of pericardial effusion on an ECHO, however he had an EF of 50%. Thyroid ultrasound showed increased vascularity with no nodules. A Tc-99 scan was done which was reported to have high total radiotracer uptake consistent with diagnosis of Graves' disease (Fig. 2). His TSH receptor antibodies were positive. He was started on propranolol 40mg three times a day, carbimazole 20mg twice a day, along with a tapering dose of ibuprofen 800mg three times a day and colchicine 500 mcg once a day. When he was seen in the clinic after a week, he showed a dramatic clinical response.

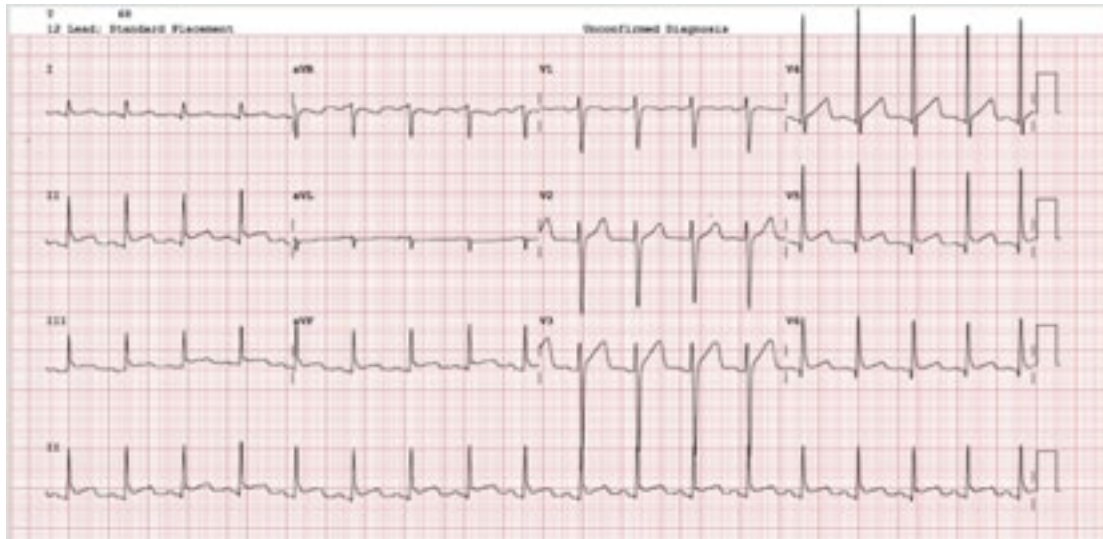


Figure 1: ECG on presentation showing widespread concave ST segment elevation without reciprocal changes and a PR segment elevation in lead aVR and PR depression in other leads, highly consistent with Stage-1 acute pericarditis

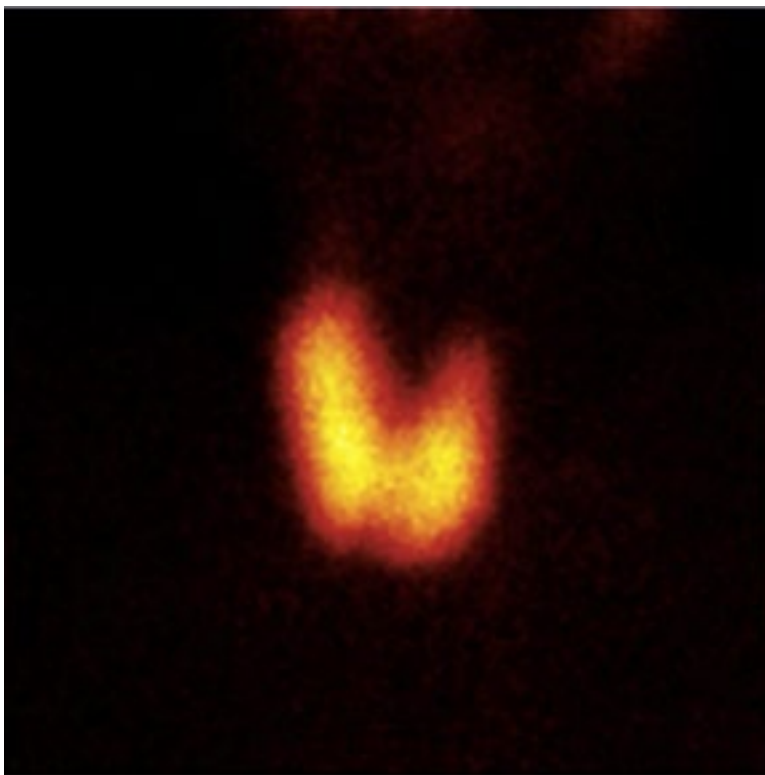


Figure 2: Tc-99 scan showing high total thyroid radiotracer uptake.

DISCUSSION

Graves disease is an autoimmune condition resulting in high levels of thyroxine (FT4) and triiodothyronine (FT3), a diffuse goiter and Graves ophthalmopathy.(5) Cardiovascular

manifestations are common, and include cardiac arrhythmias like atrial fibrillation, congestive cardiac failure, thyrotoxic cardiomyopathy and pulmonary arterial hypertension.

Acute pericarditis is one of the most common pericardial syndromes seen in clinical practice. It is diagnosed based on the presence of any two of the following criteria: chest pain, pericardial friction rub, characteristic ECG changes (new widespread ST-elevation or PR depression) and or pericardial effusion.(6) Viral infections are the most common cause of pericarditis. Other causes include bacteria, tuberculosis, myocardial infarction, trauma, malignancy and autoimmune diseases.

Several case reports have reported an association between graves disease and acute pericarditis. the first one being as early as 1958.(7) Some of these cases reports had a similar presentation to our case, where patients presented with typical clinical picture of acute pericarditis and later during evaluation they were found to have thyrotoxicosis secondary to graves disease after performing confirmatory testing.(1)(2)(3) On the other hand, some cases have reported a development of acute pericarditis in patients with established diagnosis of graves disease on treatment.(4)(8)(9) Graves disease is associated with a positive anti-TSH receptor antibodies and positive anti-thyroid peroxidase antibodies.(8) Likewise, antinuclear antibodies have been detected in patients with idiopathic recurrent acute pericarditis.(6) Autoimmune is the most acceptable mechanism to explain the association between the two entities. Clarke et al. proposed that pericarditis in Graves' disease may share the same autoimmune etiology as ophthalmomyopathy and dermopathy.(8) Another alternate explanation for this association is direct metabolic impact from acute thyrotoxicosis leading to an alteration in pericardial fat metabolism.(10) On the other hand, many case reports described pericarditis after initiation of antithyroid medication raising the possibility of pericarditis induced by antithyroid drugs. Indeed, there has been significant evidence that propylthiouracil can cause pericarditis.(9) Other antithyroid drugs can also cause acute pericarditis like iodine and carbimazole.(11)

Pericardial involvement can manifest as mild pericarditis without effusion, cardiac tamponade (12) or even myopericarditis with or without hemodynamic instability.(13)

Despite absence of a solid evidence-base pathophysiological mechanism to explain the association between graves disease and pericarditis, clinicians should be aware of this association. The management should include treatment of thyrotoxicosis and concurrent treatment of pericarditis

Reference

1. Gupta P, Chhabra L, Hiendlmayr B, Spodick DH. Thyrotoxic pericarditis: An underappreciated phenomenon. *Int J Cardiol.* 2015 Nov 1;198:32–3.
2. Tsai M-S, Yang C-W, Chi C-L, Hsieh C-C, Chen W-J, Huang C-H. Acute pericarditis: a rare complication of Graves' thyrotoxicosis? *Am J Emerg Med.* 2006 May;24(3):374–5.
3. Koo EH, Kim SM, Park SM, Park JW, Kim EK, Lee GY, et al. Acute recurrent pericarditis accompanied by Graves' disease. *Korean Circ J.* 2012 Jun;42(6):419–22.
4. Sugar SJ. Pericarditis as a complication of thyrotoxicosis. *Arch Intern Med.* 1981 Aug;141(9):1242.

5. Bartalena L. Graves' orbitopathy: imperfect treatments for a rare disease. *Eur Thyroid J*. 2013 Dec;2(4):259–69.
6. Imazio M, Bobbio M, Cecchi E, Demarie D, Demichelis B, Pomari F, et al. Colchicine in addition to conventional therapy for acute pericarditis: results of the COLchicine for acute PERicarditis (COPE) trial. *Circulation*. 2005 Sep 27;112(13):2012–6.
7. Treusch JV, Jaffe HL. Hyperthyroidism associated with presumptive acute pericarditis; a report of three cases. *Calif Med*. 1958 Sep;89(3):217–21.
8. Clarke NRA, Banning AP, Gwilt DJ, Scott AR. Pericardial disease associated with Grave's thyrotoxicosis. *QJM Mon J Assoc Physicians*. 2002 Mar;95(3):188–9.
9. Colakovski H, Lorber DL. Propylthiouracil-induced perinuclear-staining antineutrophil cytoplasmic autoantibody-positive vasculitis in conjunction with pericarditis. *Endocr Pract Off J Am Coll Endocrinol Am Assoc Clin Endocrinol*. 2001 Feb;7(1):37–9.
10. Chhabra L, Spodick DH. A comment on thyrotoxic pericarditis. *Int J Cardiol*. 2014 May 15;173(3):587.
11. Airel PS, Steele MB, Lin AH, Seidensticker DF, Shwayhat AF. Pericarditis, thymic hyperplasia, and Graves' thyrotoxicosis: case report and review of the literature. *Mil Med*. 2013 Jul;178(7):e865-869.
12. Tourniaire J, Sassolas G, Touboul P, Lejeune H, Berger M. [Tamponade caused by subacute pericarditis in Basedow's disease]. *Presse Medicale Paris Fr* 1983. 1983 Sep 17;12(32):1989–90.
13. Kukla P, Bryniarski L, Bromblik A, Szczuka K, Kawecka-Jaszcz K. [Myopericarditis complicated with cardiogenic shock mimicking acute coronary syndrome with ST elevation in a patient with hyperthyroidism and diabetes mellitus]. *Kardiol Pol*. 2008 Sep;66(9):982–6; discussion 986.