

Long-Term Survival of Gastric Adenocarcinoma without Therapy: Case Report

Ali M. Al-Amri

Abstract

Planning for treatment of gastric adenocarcinoma in a patient previously treated with partial gastrectomy for primary gastric lymphoma is difficult. Long term survival of advanced gastric adenocarcinoma is poor with therapy and even worse without treatment. The only potentially curative treatment for gastric adenocarcinoma is surgical resection with adequate margins. Palliative surgery ameliorate symptoms in about 50% of patients. Chemotherapy may play a lesser role. This report presents a case of gastric adenocarcinoma in a patient who had primary gastric lymphoma treated with partial gastrectomy. The patient is still alive 6 years after diagnosis with no signs of progression despite the fact that no active treatment was given.

From the Department of Internal Medicine and Oncology, King Fahd Hospital of the University, Al-Khobar, Kingdom of Saudi Arabia.

Received: 14 Jun 2010

Accepted: 09 Aug 2010

Address correspondence and reprint request to: Dr. Ali M. Al-Amri, MD, Department of Internal Medicine and Oncology, King Fahd Hospital of the University, Al-Khobar 31952, PO Box 40182, Kingdom of Saudi Arabia.

E-mail: aliamri49@hotmail.com

doi:10.5001/omj.2010.87

Introduction

Gastric cancer remains the second leading cause of cancer death worldwide. Prognosis has improved moderately over the past years but still with very low overall survival rate. The only potentially curative approach for patients with gastric cancer remains early detection and radical surgical resection with curative intent. The overall 5 years survival rate varies from almost nil for patients with metastatic disease to almost fifty percent survival for those patients with early resectable gastric adenocarcinoma.¹⁻⁶ Patients with localized gastric adenocarcinoma, the 5 years survival is roughly only 10%.¹⁻⁶ In general, long term survival is closely related to the stage of the disease and its anatomical location.^{7,8}

Case report

A 50-year-old male was diagnosed with primary gastric lymphoma stage I in 1994. He was then treated with surgical resection in the form of subtotal gastrectomy and billroth anastomosis. In May 2004, follow-up endoscopy showed partial gastrectomy with bile acid induced gastritis and multiple pre-anastomotic polyps probably malignant. Biopsy of gastric and anastomotic area showed findings consistent with chronic active gastritis and well differentiated adenocarcinoma grade I. (Fig. 1)

The endoscopy and biopsy were repeated in March 2005 and November 2005. The histopathological findings were consistent with well differentiated adenocarcinoma grade I of the stomach. There was no *Helicobacter pylori* seen. The malignant cells were positive for cytokeratin (CK). (Fig. 2)

During the period of follow up, patient showed no symptoms and his body weight was maintained at around 62 kg. Computerized axial tomography (CAT) scan of the chest and abdomen revealed no signs of metastatic disease. Tumor markers including CEA, CA125, CA199 and CA153 were normal. CBC, RFT and LFT were also normal.

On day 1, May 2004, the options of treatment were discussed with the patient including observation with best supportive care, surgical intervention, palliative chemotherapy or referral for second medical opinion. The patient declined any type of surgery or chemotherapy. The patient chose observation and regular follow-up.

On March 2010 the patient was evaluated in the oncology clinic and he had no symptoms. His appetite was normal with maintained body weight of 62.5 kg.

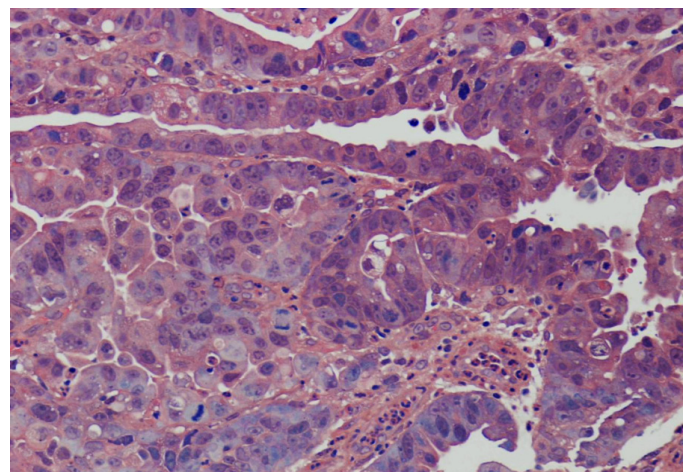


Figure 1: H&E shows well differentiated adenocarcinoma of the gastric mucosa Grade I.

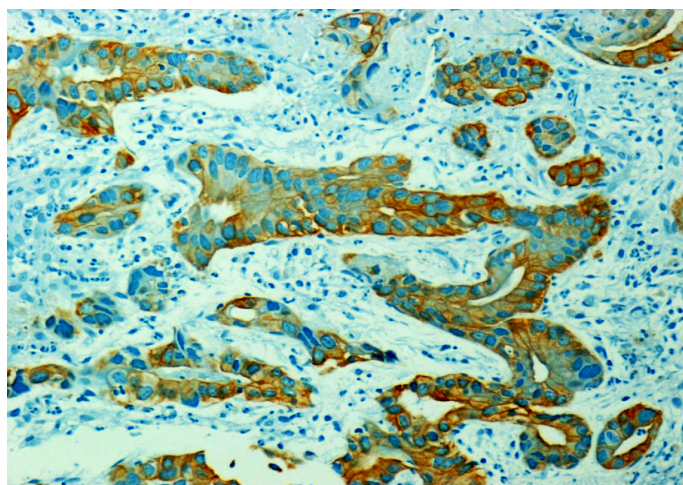


Figure 2: Shows positive immunoreactivity (diffuse and homogenous) of the tumor cells with CK.

Discussion

The histopathologic type of gastric carcinoma include well and poorly differentiated adenocarcinoma, hepatoid adenocarcinoma and denososquamous carcinoma. In the reported patient, the histopathology showed well differentiated adenocarcinoma grade I at the time of presentation and moderately differentiated adenocarcinoma grade II at the time of the last visit 5 years after the first visit.

The only possibility for curative therapy of patients with gastric adenocarcinoma remains surgical resection with free margins. Older patients or patients who had previous gastric surgery have higher postoperative mortality rate. In naïve patient with gastric carcinoma, only 50% undergo gastric resection because of advanced disease and 60% will have either local or distant relapse. In addition, only 30-50% of those who undergo exploration will achieve surgical resection with curative intent.^{6,9} In one study, the overall survival ranged from one month to 142.5 months, however, less than 5% of patients with gastric adenocarcinoma stage IV will survive 3 years.¹⁰ For unresectable advanced or recurrent gastric adenocarcinoma, treatment with systemic chemotherapy improves quality of live (QOL) with marginal survival benefits compared with the best supportive care.¹¹⁻¹³ Median survival time of patients with advanced adenocarcinoma of the stomach still remains less than one year.¹⁴ Only few patients have survived long period of time longer than five years (2%) with active therapeutic intervention.¹⁴

Our patient remains free of symptoms with normal appetite and maintained his body weight for six years. During this period, the gastric adenocarcinoma remained as a local disease with no signs of metastasis; however, the adenocarcinoma has progressed

from a grade I to a grade II adenocarcinoma. The reasons why this patient had a local malignant disease without progression over a period of five years could be due to the previous surgical resection effects on the vascular and lymphatic pathway. Secondly, it could be that the malignant disease involved only the superficial mucosa. However, the reason is not clear. At present, one should be aware of such unusual clinical courses of gastric cancer, where prognosis can deviate significantly from the average norm for unknown reasons.

Conclusion

This report presents a phenominal case of gastric adenocarcinoma in a patient who is still alive with no signs of metastasis six years after diagnosis without any active therapy.

Acknowledgements

The author reported no conflict of interest and no funding was received on this work.

References

1. Lee WJ, Lee WC, Houng SJ, Shun CT, Houng RL, Lee PH, et al. Survival after resection of gastric cancer and prognostic relevance of systematic lymph node dissection: twenty years experience in Taiwan. *World J Surg* 1995 Sep-Oct;19(5):707-713.
2. Cunningham SC, Kamangar F, Kim MP, Hammoud S, Haque R, Maitra A, et al. Survival after gastric adenocarcinoma resection: eighteen-year experience at a single institution. *J Gastrointest Surg* 2005 May-Jun;9(5):718-725.
3. Du pont BJ Jr, Cohn I Jr. Gastric adenocarcinoma. *Curr Probl Cancer* 1980;4:1-46.
4. Faivre J, Forman D, Esteve J, Gatta G. Survival of patients with esophageal and gastric cancers in Europe. *Eur J Cancer* 1998;34:2167-2175.
5. Theuer CP, Kurosaki T, Ziogas A, Butler J, Anton-Culver H. Asian patients with gastric carcinoma in the United States exhibit unique clinical features and superior overall and cancer specific survival rates. *Cancer* 2000 Nov;89(9):1883-1892.
6. Hundahl SA, Phillips JL, Menck HR. The National Cancer Data Base Report on poor survival of U.S. gastric carcinoma patients treated with gastrectomy: Fifth Edition American Joint Committee on Cancer staging, proximal disease, and the "different disease" hypothesis. *Cancer* 2000 Feb;88(4):921-932.
7. Bedikian AY, Chen TT, Khankhanian N, Heilbrun LK, McBride CM, McMurtrey MJ, et al. The natural history of gastric cancer and prognostic factors influencing survival. *J Clin Oncol* 1984 Apr;2(4):305-310.
8. Ries LA, Kosary CL, Hankey BF, Miller BA, Hurray A, Edwards BK. SEER Cancer Statistics Review 1973-1994, National Cancer Institute, NIH Publication No. 97-2789. Bethesda: Department of Health and Human Services, 1997.
9. Ajani JA. Evolving chemotherapy for advanced gastric cancer. *Oncologist* 2005;10(Suppl 3):49-58.
10. Heemskerk VH, Lentze F, Hulswé KW, Hoofwijk TG. Gastric carcinoma: review of the results of treatment in a community teaching hospital. *World J Surg Oncol* 2007;5:81.

11. Waters JS, Norman A, Cunningham D, Scarffe JH, Webb A, Harper P, et al. Long-term survival after epirubicin, cisplatin and fluorouracil for gastric cancer: results of a randomized trial. *Br J Cancer* 1999 Apr;80(1-2):269-272.
12. Pyrhönen S, Kuitunen T, Nyandoto P, Kouri M. Randomised comparison of fluorouracil, epirubicin and methotrexate (FEMTX) plus supportive care with supportive care alone in patients with non-resectable gastric cancer. *Br J Cancer* 1995 Mar;71(3):587-591.
13. Glimelius B, Hoffman K, Haglund U, Nyrén O, Sjöden PO. Initial or delayed chemotherapy with best supportive care in advanced gastric cancer. *Ann Oncol* 1994 Feb;5(2):189-190.
14. Yoshida M, Ohtsu A, Boku N, Miyata Y, Shirao K, Shimada Y, et al. Long-term survival and prognostic factors in patients with metastatic gastric cancers treated with chemotherapy in the Japan Clinical Oncology Group (JCOG) study. *Jpn J Clin Oncol* 2004 Nov;34(11):654-659.